

Expert care at a critical time

SURGICAL REPAIR OF GASTROSCHISIS IN NEONATES

Helen Yeo RGN

Neonatal Unit Sister, University Hospital of Wales, Cardiff

Gastroschisis is a life threatening condition which demands urgent treatment, creating great anxiety for the parents of affected babies. Where nurses can explain surgical procedures to parents and provide them with support in the neonatal unit, this anxiety can be greatly reduced.

Gastroschisis is a congenital defect of the abdominal wall which occurs in one in every 30,000 births. The contents of the abdomen herniate through a full thickness cleft in the abdominal wall near the umbilicus. The defect itself is often small compared to the size of the extruding viscera, and without immediate treatment and repair the blood supply to the intestines will be catastrophically impaired and the baby will die from strangulation and gangrene of the gut.

The condition has been known about and recorded since the Renaissance and surely long before then. The first reports of a successful repair were published in the early 1800s (Lister and Irving, 1990).

Embryology

The precise embryogenesis of gastroschisis is not clear. The problem is that a similar condition, exomphalos, where abdominal contents herniate into the base of the umbilical cord, occurs simultaneously; the difficulty comes in deciding how each has developed in the fetus. It seems that both defects occur around the fifty-second day, when the oblique and rectus abdominis muscles form.

Gastroschisis literally means cleft belly; it is a defect of the muscle of the abdominal wall which allows the contents to extrude. The gap in the wall is usually fairly small, but can vary from a few centimetres to one extending from the sternum to the pubic symphysis. It occurs next to the umbilicus and most often to the right. Occasionally only a short length of gut extrudes but more commonly the extrusion comprises all the small intestine and much of the colon, and sometimes the stomach, testes or uterus, gall bladder, liver, or urinary bladder. There is no sac covering the eviscerated gut, which is usually dilated, thickened and showing evidence of fetal peritonitis due to the irritant action of the amniotic fluid, and the intestine is sometimes shortened and has atresias and malrotations (Figure 1).

As gastroschisis is congenital, malformations additional to those affecting the gut are uncommon. Mothers are likely to be under 20, and the child is their first born (Lister and Irving, 1990). There are no complications of the pregnancy but the birth weight can be as low as 2,500g at term.

Diagnosis

Ultrasound scanning during pregnancy now means that these babies can be diagnosed *in utero* and the defect accurately assessed. It also facilitates the detection of exomphalos, which carries a high

KEY POINTS

Yeo, H. (1993) Expert care at a critical time: surgical repair of gastroschisis in neonates. *Child Health*, 1: 2, 74-78.

1. Diagnosis *in utero* means the baby can be delivered in a neonatal surgical unit.
2. Advances in intravenous nutrition have greatly improved the prognosis for these babies.
3. Parents need the support of other parents with the same problem.
4. Babies with uncomplicated gastroschisis generally survive.

incidence of chromosomal and other abnormalities, meaning parents can then be counselled.

When gastroschisis is diagnosed, the mother will be referred to a maternity hospital with a neonatal surgical unit, which provides the best chance of a successful outcome in delivery, as the mother does not have to make a long journey in labour. It also enables the surgical team of the receiving hospital to be electively ready to operate soon after birth. The team should be notified when the scan diagnosis is made in order to give advice and monitor future scans, as the irritant effect of the amniotic fluid can cause irreparable damage to the eviscerated gut. This could necessitate the surgical removal of most of the gut at birth, giving the baby very little chance of a normal life. If there is evidence of inflammation of the bowel on scan, labour is usually induced early – at 32-34 weeks. The risk of caesarean section to the mother and baby is not justified, as the intestine suffers little damage or bacterial contamination during labour.

When the mother is referred to the delivering hospital, the surgeons will explain the surgery to her and later ask both parents (if appropriate) to sign a consent-for-surgery form. A member of the neonatal staff will answer questions and give any written information on the unit, including help with accommodation, and then take the mother to the unit and introduce her to the staff. At this stage the mother will be asked to consider expressing her milk for the baby for a few weeks, even if she does not intend to breastfeed.

At birth

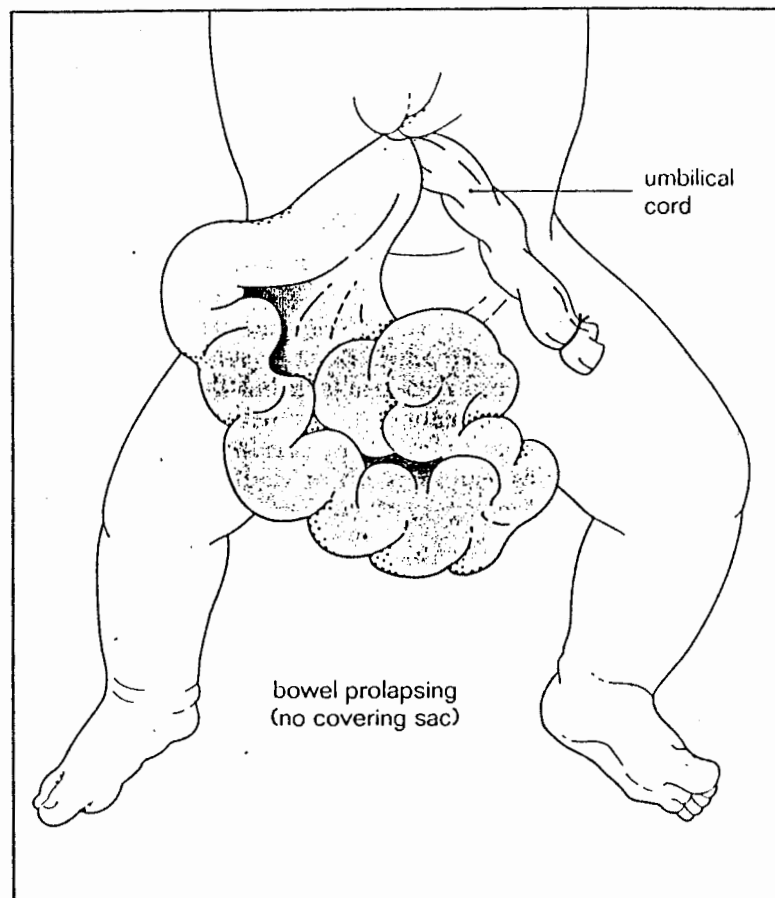
The baby is often growth retarded and wasted. The defect is obvious and the intestines may show evidence of fetal peritonitis. Impaired circulation to the bowel is common due to pressure exerted by the small hole through which it has herniated, and sometimes the bowel is gangrenous. Immediate surgery is necessary to prevent further damage to the circulation of the intestine and to salvage the remains of the bowel in the cases of gangrene.

The baby will be nursed in the intensive care room in an incubator for warmth – there is a great risk of hypothermia due to rapid heat loss from the exposed gut. Nursing care to prevent this saves valuable time otherwise spent warming the baby and improving perfusion before surgery. In order to minimise heat and water loss from the bowel, the intestines are wrapped in cling film, which is easy to handle and allows visual access. Some units place the lower half of the baby in a draw-string intestinal bag to cover the defect while leaving it visible.

A number eight nasogastric (NG) tube is passed and aspirated continuously on low suction to keep the bowel decompressed – large amounts of bile will be excreted from the damaged gut. Intravenous (IV) fluids of colloids and crystalloids are started quickly to prevent hypoglycaemia and to correct perfusion for theatre, and IV antibiotics are commenced. Advice and help is given to the mother to express her milk.

The operation

The cling film or protective bag is left in place until the baby is anaesthetised in theatre – throughout the operation care is taken to keep the exposed bowel warm. The bowel is cleaned with aqueous chlorhexidine and milked gently to help decompression. The hole in the abdominal wall has to be enlarged before the gut can be returned, and the abdominal wall is thoroughly stretched by the surgeon's fingers, with a thumb inside the abdomen. This is to increase the capacity of the abdomen for the large amount of



■ Figure 1. The eviscerated gut is not covered by a sac, and the intestine is sometimes shortened, with atresias and malrotations.

bowel. The gut is inspected from end to end for atresias and kinks, and gangrenous bowel resected. The abdomen is then closed in layers.

In about 20 per cent of cases, the gut herniates early in fetal life, resulting in a very small abdominal cavity. Of these, 10 per cent need a skin flap closure because there is not enough muscle, and the other 10 per cent need a silastic bag to be stitched to the opening of the defect to accommodate the intestines. The pouch reduces in size every one to two days over a 10 day period and eventually sloughs off leaving a covered membrane which contracts and epithelialises (secondary closure).

Postoperative nursing care

Most babies are electively ventilated after surgery. Respiration is often embarrassed when the abdomen is very tense from the closure – IV pain relief can be given. Ventilatory support is usually only necessary in the first 48 hours, except in very tight closures or where a silastic pouch is used. IV pain relief is weaned before taking the baby of the ventilator and rectal suppositories of paracetamol are used.

It is important for the nurse to ensure the abdomen is kept decompressed by continuous low suction on the NG tube. This prevents swelling of the gut and removes copious secretions. As a result, the baby is more comfortable and should not vomit.

Because of the damage to and handling of the gut, a long period of paralytic ileus can be expected. Metronidazole is continued intravenously for five to seven days to sterilise the bowel, and while no bowel sounds are heard, IV fluids are given – a central venous

REFERENCES

Lister, J. and Irving, I. (1990, 3rd Edn) Neonatal Surgery. Butterworth, Oxford.
 Ludman, L. (1992) Emotional development after major neonatal surgery. *Paed. Nurs.*, May.

BIBLIOGRAPHY

Andrews, K. and Wills, B. (1992) A protocol for pain relief in neonates. *Prof. Nur.*, 8, 8, 528-32.
 Klaus, S. and Faranoff, A.A. (1988, 3rd Edn) Care of the High Risk Neonate. Saunders, Marshall Avroy.
 Robertson, N. (1986) A Manual of Neonatal Care. Edward Arnold, London.
 Stewart, A. (1989) Preparing parents for neonatal units. *Midw., HV and Comm. Nur.*, 25, 10.

Complications

line is used so that a concentrated formula of total parenteral nutrition can be given. The high survival rate of these babies is largely due to the improvements in IV feeding techniques over the last 10 years: calories (at least 100 per kg a day) and proteins can be controlled to maximise growth. The sterility and patency of the line is of vital importance in preventing life-threatening septicaemias and repeated resitings.

The wound will be very tense and may gape as healing occurs, and so observation for signs of infection is necessary. When bowel sounds are heard and bile secretions diminish, the continuous suction is stopped. Four-hourly aspirations of the NG tube are carried out and clear solutions, such as solution A (saline with electrolytes) or Dioralyte, are given, starting with 3-5ml hourly. If the baby tolerates this without vomiting or abdominal distension, the mother's breast milk can be started in the same amounts after 12-24 hours, though some units start with 1ml hourly and increase it by 1ml every 12 hours as tolerated. Babies who have a silastic pouch in place are not fed until secondary closure has taken place, and IV fluids are decreased while the oral fluids are slowly increased.

Atresias of the gut or volvulus are common complications of gastroschisis; symptoms include abdominal distension with vomiting, no bowel sounds and an ill, listless or collapsed baby. A return to theatre for the removal of the obstruction is necessary.

The process of weaning from IV nutrition to oral feeding takes anything from a week to a few months – a difficult time for the parents. The baby might have periods of infection meaning antibiotics and total IV feeding will be necessary again. Even the milk may have to be changed from the mother's expressed breast milk to Progestamil or Chix, which is more easily absorbed. The baby will be hungry and miserable – parents can play a vital role in comforting their baby.

Great Ormond Street Hospital carried out a study of babies who had undergone major neonatal surgery (Ludman,1992); they were found to be more temperamental in their first year of life than healthy babies, and had more disturbed sleeping patterns, which often persisted up to the age of three. This was in spite of parents staying in the unit with their baby. Units specialising in surgery often a system by which the parents of a surgical baby can be put in contact with other parents with the same problem for long-term advice and support.

Prognosis

The outcome for gastroschisis is very good. Once feeding is established, tolerated and absorbed, and the baby is gaining weight satisfactorily, there are usually no further problems. When the baby has been discharged the surgeons will follow him or her up for a few months. Babies who have had a skin closure have a ventral hernia which is closed at 12-18 months, and baby boys who have had silastic pouches often develop inguinal hernias. If there are no problems at discharge the parents can expect no further complications.

Few babies die with uncomplicated gastroschisis; the ones with the most long-term problems have had large amounts of gangrenous bowel removed. All babies with gastroschisis present the nurse with a special challenge: in the drama and urgency of delivery and operation, and then the three to five month expert care of a sick baby and anxious parents. The reward comes with the visit to the ward, at one year old, of a chubby, healthy baby.